

RESEARCH

Open Access

Retractorless brain surgery: technical considerations



Wael Mohamed Nazim^{1*}  and Mohamed Abdelrahman Elborady²

Abstract

Background: Retraction is necessary to access deep areas in the brain and skull base, but prolonged and forceful use of fixed retraction might be injurious. Several techniques were developed, in the concept of minimally invasive neurosurgery, to eliminate or minimize the use of fixed retractors. The authors discuss the technical considerations and limits in applying dynamic retraction in brain surgery for a variety of lesions using different approaches.

Results: We retrospectively collected 123 cases with brain lesions in diverse locations, were dynamic retraction, using the tools in the operator hands and was achieved successfully instead of fixed retraction. Cases with aneurysms were excluded, although retraction was applied during clipping only. Superficial and large masses that do not require fixed retraction as a routine were excluded also. We relied mainly on patient positioning to benefit from the gravity, proper design of the craniotomy, arachnoid dissection, cerebrospinal fluid aspiration, and internal decompression of the mass when possible.

Different approaches for different lesions were utilized in our patients, subfrontal or pterional and their modifications in 45.5% of cases, suboccipital in 21.1%, retrosigmoid in 13%, the interhemispheric approach in 10.5%, transcortical to lateral ventricles in 7.3%, and posterior subtemporal in 2.4%.

Dynamic retraction with the surgical tools was used successfully in all cases except 7 patients (5.6%) where we had to use fixed retraction transiently.

Conclusion: Several considerations are helpful and amenable to achieve successful brain surgery without fixed retraction. Utilizing the gravity, unlocking of the brain, choosing the surgical corridor, cerebrospinal fluid suctioning, and mastering of the microsurgical techniques are the keys.

Keywords: Retractorless brain surgery, Dynamic retraction, Minimally invasive neurosurgery, Retraction injury, Brain edema

Background

Brain retraction plays an important rule to reach deep seated lesions to protect surrounding structures and to avoid brain matter transgression. From simple hand retractors to more advanced self-retaining systems, the development continued to improve their efficacy and to minimize defects like assistant fatigue, hand tremors, retractor slippage and brain injury [1, 2]..

Retraction injury to neural and vascular structures is the most devastating and unwanted complication of fixed retractors. There are several aspects of retraction injury that may occur especially with excessive, prolonged retraction for large lesions. Increased intracranial pressure (ICP) secondary to brain edema and brain contusion, ischemia, venous infarction, and cranial nerve injuries are complications of vigorous sustained retraction [1, 3, 4].

Methods and techniques to minimize those side effects like special retractors did not gain popularity [1, 2].

The concept of minimally invasive neurosurgery was developed to access deep lesions efficiently while

* Correspondence: waelmnaz@med.bsu.edu.eg;
wael.mohamed.nazim@gmail.com

¹Neurosurgery Department, Faculty of Medicine, Beni-Suef University, Beni-Suef, Beni-Suef, Egypt

Full list of author information is available at the end of the article

minimizing surrounding tissue injury. So, with the advancement of the microscopes, surgical tools, intraoperative image guidance, and other operating room devices, together with meticulous surgical technique, the avoidance of using fixed retraction has been shown successful and eliminates possible associated brain injury [1, 5, 6].

In this study, we present our experience in using dynamic retraction in cases with skull base and brain surgery without advanced operating room equipment.

Methods

This is a retrospective study of 123 surgical procedures for a variety of deep brain and skull base lesions, in which fixed retraction was successfully replaced by dynamic retraction using the surgical tools in the surgeons' hands. We excluded cases with aneurysms, although fixed retraction was used during clipping only. Superficial and large masses that do not require fixed retraction as a routine were excluded also. Steps and technical points that help to avoid fixed retraction are discussed.

We start with proper patient positioning to benefit from the gravity. Although this is not specific to avoid retraction, but its proper application is invaluable. For example, in interhemispheric and infratentorial approaches, we can utilize the falx or the tent, retrospectively, to retain one part of the brain and let the gravity pull on another. The same idea is applied in approaches related to the skull base (Figs. 1 and 2)

The design of the craniotomy is crucial also to avoid the use of unnecessary retraction. Few millimeters in the bone flap can make a considerable difference. The craniotomy should cross the dural folds in interhemispheric and supracerebellar approaches, if we have to use interhemispheric or supracerebellar routes (Figs. 2 and 3)

The introduction of the microscope is next to flap elevation and was used in all procedures. Early magnification allows addressing basal cisterns to aspirate cerebrospinal fluid (CSF), opening natural corridors, cutting the arachnoid anchoring neural and vascular structures, and defining the brain tumor interface.

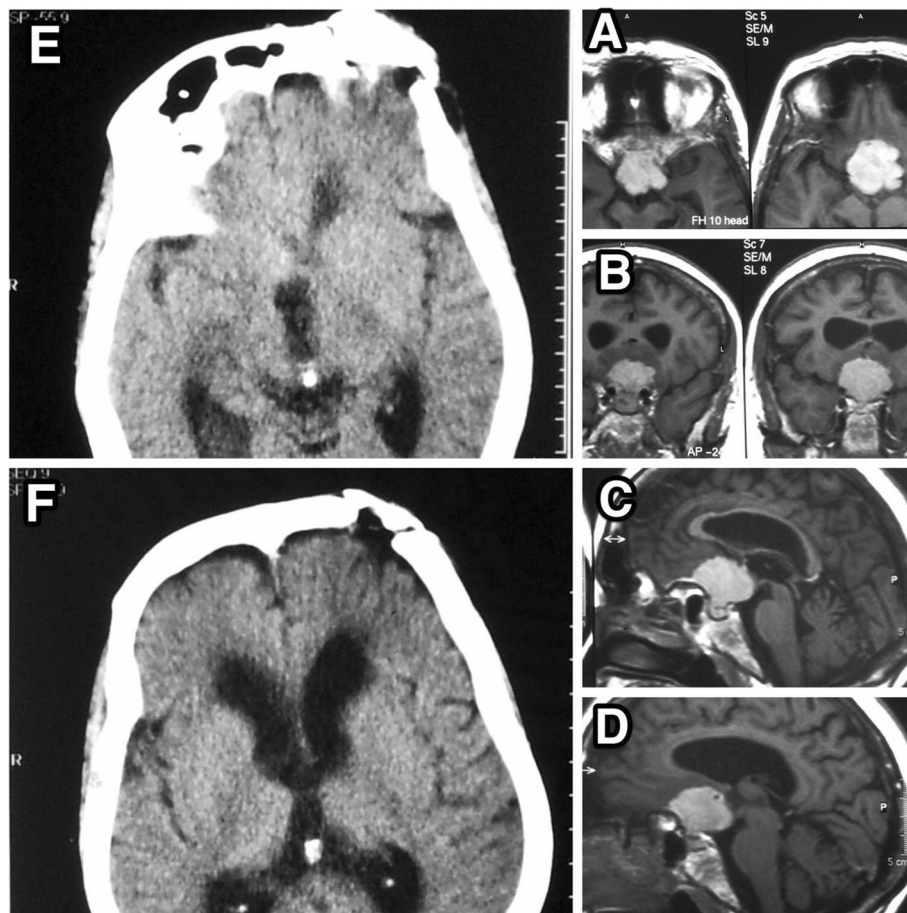


Fig. 1 Suprasellar meningioma operated through left subfrontal approach (side of more affected optic nerve) in supine position. **A-D** Preoperative MRI. **E, F** Postoperative CT scan

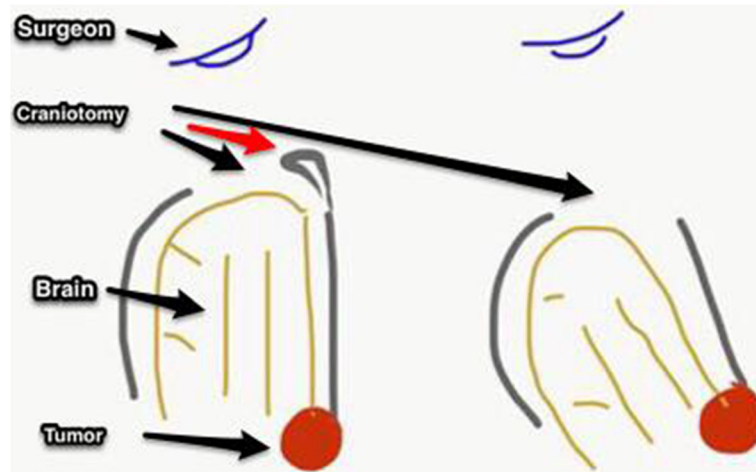


Fig. 2 Diagram of lesion in the sellar suprasellar region (left part), demonstrating the importance of patient positioning and design of craniotomy (right part) to avoid fixed retraction

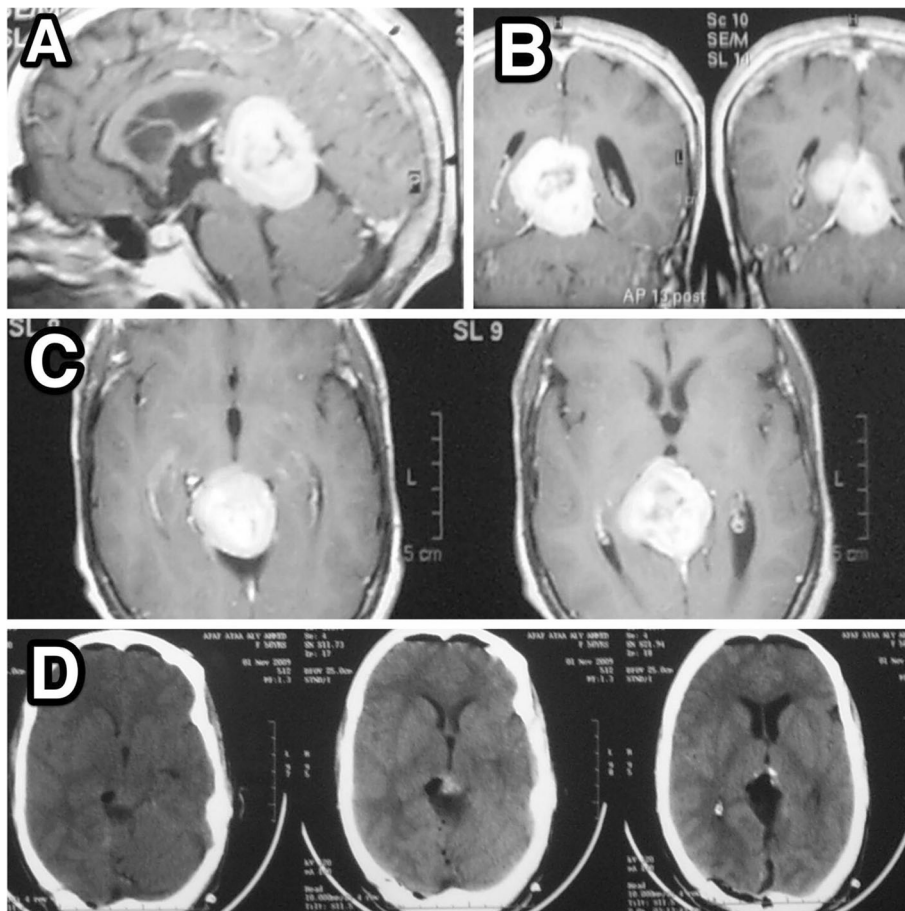


Fig. 3 Falcotentorial meningioma operated through posterior interhemispheric approach in $\frac{3}{4}$ prone position. The right side was dependent. **A-C** Preoperative MRI. **D** Early postoperative CT scan

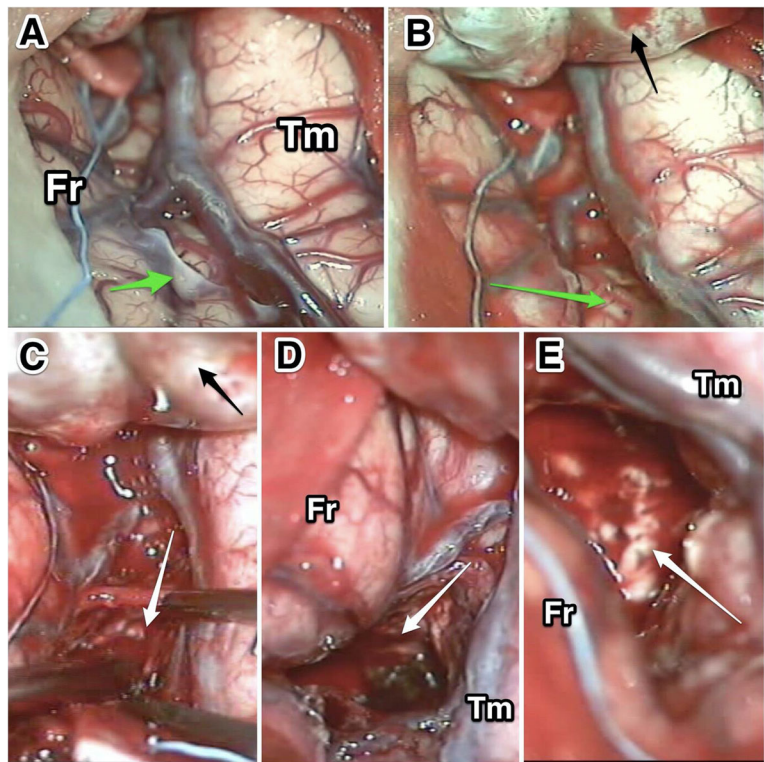


Fig. 4 Trans-sylvian approach for resection of right insular glioma. **A, B** Opening the arachnoid of the fissure. **C, D** Tumor removal. **E** The tumor bed after excision of the tumor. Fr, frontal lobe; Tm, temporal lobe. Green arrow, Sylvian fissure. White arrow, tumor and tumor bed. Black arrow, sphenoid ridge

Brain unlocking through extensive arachnoid dissection to open the cisterns and to untether lobes is crucial nearly in a lot of cases (Fig. 4). Aspiration of CSF reduces the intracranial pressure, thus limiting the need for prolonged retraction, although not always possible as not all approaches access the basal cisterns. Preplanned lumbar drain was used in 2 cases (1.6%) only as it is not preferred by the authors, while intraoperative ventricular tapping was done in 4 cases (3.2%).

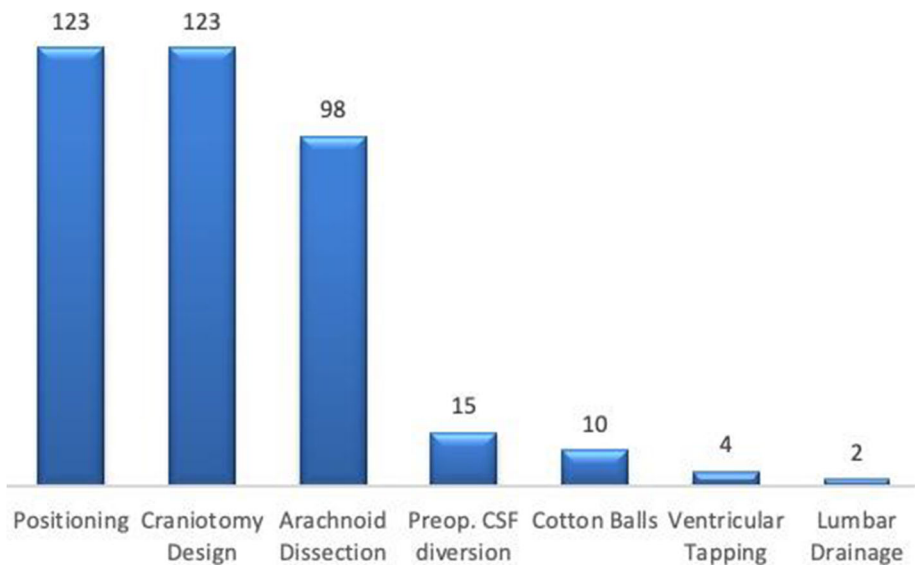


Fig. 5 Distribution of maneuvers used to eliminate fixed retraction in our patients. The number in each column refers to the number of patients where this maneuver was applied

Preoperative CSF diversion in patients with hydrocephalus that may endanger their life upon preparation for tumor excision was done in 15 patients (12.2%).

Finally, internal decompression of the tumor allows the walls of the tumor to fall away from normal surrounding tissues and to be easily dissectible; this is an important step if not contraindicated in some lesions.

There are other maneuvers that have been employed and helped to eliminate using fixed retractors. In approaches related to dural folds (interhemispheric and lateral supracerebellar infratentorial approaches), cotton rolls inserted between the falx or the tent and the brain in 10 cases (8.1%). Those rolls retain the brain, do not obstruct the operative field, and they are softer than the metallic self-retaining retractors.

All patients received mannitol 0.5–1 gm/kg before elevation of the bone flap followed by furosemide to reduce the intracranial pressure (ICP). Steroids (dexamethasone 10 mg) were given in cases with tumors to minimize edema from the mass or manipulation of the brain (Fig. 5).

Results

For the procedures done, different approaches were used in our patients as the following: subfrontal or pterional and their modifications in 56 (45.5%) procedures, suboccipital in 26 (21.1%), retrosigmoid in 16 (13%), the interhemispheric approach in 13 (10.6%), transcortical to the lateral ventricles in 9 (7.3%), and posterior subtemporal in 3 (2.4%) (Fig. 6).

Different positions were employed (Fig. 7). Supine position was the most frequent in 87 lesions (70.7%), out of them 14 (11.3%) with head tilt. The prone and three

quarter prone were next in frequency in 31 (25.2 %) cases, while the park bench was the least common (5 cases [4%]). Sitting positions was not utilized as it is not preferred by the authors.

Regarding the lesion types encountered in our patients, meningioma was the most frequent. It was found in 42 patients (34.1%). Followed by glioma in 15 (12.1%), craniopharyngioma in 11 (9.7%), and schwannoma in 5 (4%). Other tumors were found in 15 cases (12.1%), tumor like lesions in 4 (3.2%), and other lesions in 31 (25.1%) (Fig. 8)

Dynamic retraction with the surgical tools was achieved properly in all cases (Video 1) except 7 procedures (5.6%), where we had to use fixed retraction transiently due to persistent intracranial hypertension and large lesion size. In addition, frontal or temporal lobectomy was done in 3 (2.4 %) out of the later cases.

Discussion

Brain manipulation/retraction is an essential step to access deep lesions in the brain parenchyma or the base of the skull. Throughout the development of neurosurgery, retraction was developed from simple handheld to self-retaining retractors for the sake of freeing the surgeons' hands, minimizing fatigue and tremors, especially with the introduction of micro-neurosurgery [1, 2].

Those benefits are not without hazards, as there are possible risks of tissue injury associated with prolonged retraction, especially at the tip of the retractor. Retraction injuries occur secondary to direct mechanical trauma or from vascular compromise in the form of edema and ischemia. It is difficult to assess or expect the amount of injury, but the damages range from mild

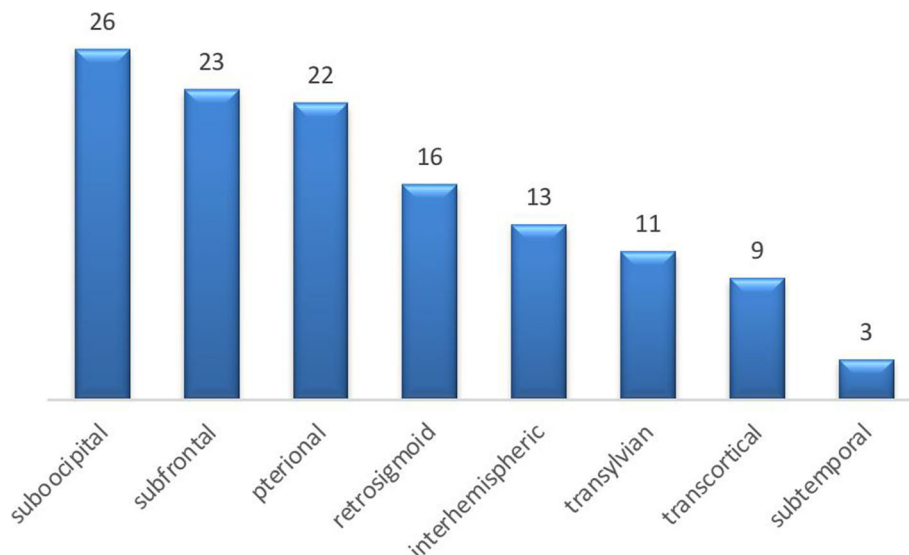


Fig. 6 Chart showing the distribution of approaches used. The number in each column refers to the number of patients where this maneuver was applied

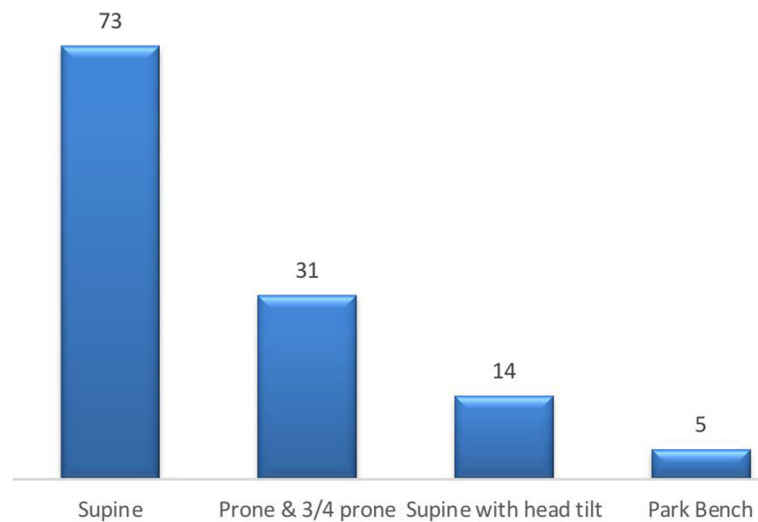


Fig. 7 Chart showing operative positions employed in our series. The number in each column refers to the number of patients where this maneuver was applied

transient edema to chronic cortical changes, massive edema, and even mortality. It has been estimated that brain retraction injury occurs in approximately 10% of major cranial base tumor procedures or 5% of intracranial aneurysm surgeries [3, 4, 7–10].

This has led to the appearance of techniques to predict or to minimize that risk. Preoperative imaging for detection of susceptible parts of the cortex and planning the position of retractors were studied. Intraoperative methods to detect cerebral damage like monitoring of local cerebral blood flow, intracranial pressure, and cerebral metabolism using microdialysis, also were discussed.

Other methods are the technical modifications of the retractors to lessen the pressure from metallic retractors, like sponge or balloon-based retractors, or the use of Fogarty catheters filled with air. None of the previous methods had gained popularity. The other option is the intermittent release of the retractor every 5 min, and the use of multiple retractors instead of one to avoid localizing the pressure on a small area of the brain [1, 10–15].

In concordance with several authors, we focused in this study on the success of avoiding the use of fixed retraction, but dynamic retraction using the surgical instruments in the surgeon hands. This could be achieved

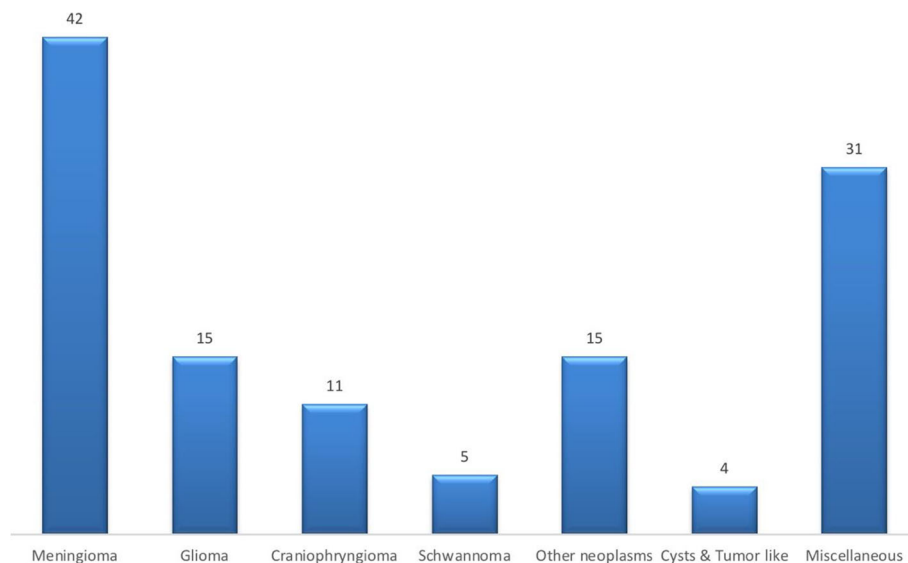


Fig. 8 Lesion types in this series

by relying on basic surgical steps that are amenable when applied properly, and in the absence of sophisticated intraoperative equipment. The main steps are proper patient positioning to benefit from the gravity, design of the craniotomy, choice of natural corridors to avoid brain transgression, proper arachnoid dissection, and CSF aspiration [1, 6, 16–22].

Patient positioning and craniotomy design are two simple and effective steps to avoid fixed retraction, although not specific for. Their proper application benefits from the gravity to pull on the brain, avoid unnecessary retraction, and use the dual folds to retain parts of the brain instead of retracting them. We used cotton rolls as soft retraction in a number of cases where the approach is between the falx or the tent from one side and the brain from the other side. This is similar to the idea of Spina et al. who used Fogarty catheter filled with air as soft retractors [16].

The craniotomy flap design is important too, adding few millimeters in the skull base, or to cross the dural sinuses in interhemispheric approaches avoids undue retraction [1, 6].

Microscopic magnification to open subarachnoid spaces, address the brain tumor interface and later tumor debulking to decrease the intracranial pressure is a must. Extensive arachnoid dissection unlocks the brain lobes, allows CSF aspiration thus minimizes the ICP and limits the need for retraction. We begin to open arachnoid cisterns before handling the tumor in all cases except in approaches not related to cisterns with large subarachnoid spaces, like interhemispheric approach, where we had to do ventricular tapping. Some authors reported the use of arachnoid retraction to avoid fixed retraction using sutures or clips applied to the arachnoid temporarily during surgery [1, 5, 16, 17, 23].

The use of special surgical tools can help the surgeon to apply dynamic retraction more easily. Examples are the use of microscope with mouth piece, lighting instruments, and single shaft tools [1, 5, 7]. Their use unblocks the field, free the operator hands, and limit repeated change of the microspore angle [1, 6]. In our study, we used the navigation in some cases as it was not always available, but otherwise we relied on basic microsurgical tools and the above-mentioned methods.

Other measures to reduce intracranial pressure were applied infrequently in our patients, like lumbar drainage and ventricular tapping. Preplanned lumbar drain, although advised by some authors, was used in 2 cases (1.6%) only as it is not preferred by the authors, while intraoperative ventricular tapping was done in 4 cases (3.2%) where no access to basal cisterns to aspirate CSF [16, 19].

We had to use fixed retractors transiently in 7 cases (5.7%) due to persistent high intracranial pressure or

large masses where the surgeon needs to use both hands in the field unhindered by retracting the brain. This agrees also with similar studies that dynamic retraction was not always possible, and the authors were obliged to use fixed retraction in some cases, although we did not have matching intraoperative facilities [1, 5, 6, 21, 22].

Conclusion

Many intracranial procedures can be done with excellence using fixed retraction, but with the risk of retraction injury which is not accepted nowadays as it can cause significant morbidity or even mortality. Techniques and modifications of self-retaining retractor systems to decrease retraction injury did not gain popularity.

Dynamic retraction using the surgical tools can be used safely in most if not all cases with deep seated brain lesions. It should be the outcome of daily application of basic principles and eased by the use of special surgical tools and equipment.

Abbreviations

CSF: Cerebrospinal fluid; CT: Computerized tomography; gm: Gram; ICP: Intracranial pressure; kg: Kilogram; MRI: Magnetic resonance imaging; mg: Milligram

Supplementary Information

The online version contains supplementary material available at <https://doi.org/10.1186/s41983-021-00329-w>.

Additional file 1: Video 1. Right trigeminal neuralgia operated through suboccipital approach in supine position with head tilt.

Acknowledgements

Not applicable

Authors' contributions

W.N. shared in data collection, analysis, and prepared the manuscript for publication. M. E. shared in data collection and review of the manuscript. Both authors read and approved the final manuscript.

Funding

This study is funded by the authors in all aspects (data collection, analysis, and writing the manuscript).

Availability of data and materials

Data used and analyzed in this study are available from the authors on reasonable request.

Declarations

Ethics approval and consent to participate

This work has been accepted by the ethics committee in the Department of Neurosurgery, Faculty of Medicine, Beni-Suef University. Reference number is not applicable. It has been approved in November 2016. Consent to participate has been approved also by the same committee. Informed consent was obtained from patients involved in this study.

Consent for publication

Not applicable

Competing interests

The authors declare that they have no competing interests.

Author details

¹Neurosurgery Department, Faculty of Medicine, Beni-Suef University, Beni-Suef, Beni-Suef, Egypt. ²Cairo University, Cairo, Egypt.

Received: 10 January 2021 Accepted: 30 May 2021

Published online: 23 July 2021

References

1. Spetzler RF, Sanai N. The quiet revolution: Retractorless surgery for complex vascular and skull base lesions - Clinical article. *J Neurosurg.* 2012 Feb;116(2):291–300. <https://doi.org/10.3171/2011.8.JNS101896>.
2. Assina R, Rubino S, Sarris CE, Gandhi CD, Prestigiacomo CJ. The history of brain retractors throughout the development of neurological surgery. *Neurosurg Focus.* 2014 Apr 1;36(4):E8. <https://doi.org/10.3171/2014.2.FOCUS13564>.
3. Xu W, Møllergård P, Ungerstedt U, Nordström CH. Local changes in cerebral energy metabolism due to brain retraction during routine neurosurgical procedures. *Acta Neurochir (Wien).* 2002;144(7):679–83. <https://doi.org/10.1007/s00701-002-0946-1>.
4. Rosenorn J, Diemer N. The risk of cerebral damage during graded brain retractor pressure in the rat. *J Neurosurg.* 1985;63(4):608–11. <https://doi.org/10.3171/jns.1985.63.4.608>.
5. Lanzino G. Retractorless brain surgery. *J Neurosurg.* 2012;116(2):290. <https://doi.org/10.3171/2011.8.JNS11627>.
6. Sanai N, Spetzler RF. Defining excellence in vascular neurosurgery. *Clin Neurosurg.* 2010;57:23–7.
7. Andrews RJ, Bringas JR. A review of brain retraction and recommendations for minimizing intraoperative brain injury. *Neurosurgery.* 1993;33(6):1052–63.
8. Wu R, Kang Z. Investigation on the effects of brain retraction on local cerebral metabolism utilizing microdialysis. *Clin Med Res.* 2016;5(4):77–81. <https://doi.org/10.11648/j.cmr.20160504.13>.
9. Hongo K, Shigeaki K, Sugita K, Yokoh A. Monitoring retraction pressure on the brain. *J Neurosurg.* 1987;66(2):270–5. <https://doi.org/10.3171/jns.1987.66.2.0270>.
10. Jackson C, Ehresman J, Vivas-Buitrago T, Bettgowda C, Olivi A, Quinones-Hinojosa A, et al. Retractorless surgery: strokes, edema, and gliosis outcomes following skull base surgery. *J Neurol Surg B Skull Base.* 2018;79(S 01):S1–S188. <https://doi.org/10.1055/s-0038-1633350>.
11. Andrews RJ, Muto RP. Retraction brain ischaemia: cerebral blood flow, evoked potentials, hypotension and hyperventilation in a new animal model. *Neurol Res.* 1992;14(1):12–8. <https://doi.org/10.1080/01616412.1992.11740004>.
12. Zhong J, Dujovny M, Perlin AR, Perez-Arjona E, Park HK, Diaz FG. Brain retraction injury. *Neurol Res.* 2003;25(8):831–8. <https://doi.org/10.1179/016164103771953925>.
13. Little AS, Liu S, Beeman S, Sankar T, Preul MC, Hu LS, et al. Brain retraction and thickness of cerebral neocortex: An automated technique for detecting retraction-induced anatomic changes using magnetic resonance imaging. *Neurosurg.* 2010;67(Suppl 1):277–82.
14. Okamoto J, Iida M, Nambu K, Fujie MG, Umezaki M. Development of multi-DOF brain retract manipulator with safety method. In: IEEE International Conference on Intelligent Robots and Systems [Internet]. 2003. p. 2594–9. Available from: <http://ieeexplore.ieee.org/document/1249261/>.
15. Fukuhara A, Tsujita T, Sase K, Konno A, Jiang X, Abiko S, et al. Optimization of retraction in neurosurgery to avoid damage caused by deformation of brain tissues. In: 2014 IEEE International Conference on Robotics and Biomimetics, IEEE ROBIO 2014 [Internet]. 2014. p. 588–94. Available from: <http://ieeexplore.ieee.org/document/7090394/>.
16. Spina G, Versari P. Bubbles in the head: a new method for brain retraction during craniotomy. *Acta Neurochir (Wien).* 2011;153(9):1807–11. <https://doi.org/10.1007/s00701-011-1085-3>.
17. Schatlo B, Radovanovic I. Clip-retraction of the superficial Sylvian vein to enhance visualization in “retractorless” aneurysm surgery. *Acta Neurochir (Wien).* 2016;158(2):229–32. <https://doi.org/10.1007/s00701-015-2684-1>.
18. Kretschmer T, Heinen C, Schmidt T. Retractorless surgery of vascular lesions. In: July J, Wahjoepramono EJ, editors. *Neurovascular Surgery: Surgical approaches for neurovascular diseases.* Springer Open; 2019. p.255–267.
19. Nakao N. Retractorless surgery for a pineal region tumor through an occipital transtentorial approach. *Neurosurg Focus.* 2016;40(January):15412.
20. Yu LH, Sen YP, Zheng SF, Kang DZ. Retractorless surgery for anterior circulation aneurysms via a pterional keyhole approach. *World Neurosurg.* 2015;84:1779–84.
21. Liu JK, Jyung RW. Retractorless translabyrinthine approach for resection of a large acoustic neuroma: operative video and technical nuances. *Neurosurg focus.* 2014;36:1.
22. Wang X, Hui LY, Mao Q. Retractorless surgery for third ventricle tumor resection through the transcallosal approach. *Clin Neurol Neurosurg.* 2017; 155:58–62.
23. Uluc K, Cikla U, Baggott C, Baskaya M. A novel technique of arachnoid retraction in microneurosurgical resection. *J Neurol Surg B Skull Base.* 2015; 76(S 01):042.

Publisher's Note

Springer Nature remains neutral with regard to jurisdictional claims in published maps and institutional affiliations.

Submit your manuscript to a SpringerOpen[®] journal and benefit from:

- Convenient online submission
- Rigorous peer review
- Open access: articles freely available online
- High visibility within the field
- Retaining the copyright to your article

Submit your next manuscript at ► [springeropen.com](https://www.springeropen.com)