Shao *et al.*
Egypt J Neurol Psychiatry Neurosurg (2024) 60:9
https://doi.org/10.1186/s41983-023-00781-w

The Egyptian Journal of Neurology, Psychiatry and Neurosurgery

CASE REPORT

Open Access

Application of unilateral biportal endoscopy technique to resect a thoracic spinal intradural extramedullary meningioma: technical report and review of the literature

Rongxue Shao[1,2], Wei Cheng[1], Wei Zhang[1,2*], Jiaming Liang[1], Liqi Ruan[1], Chengyue Zhu[1] and Hao Pan[1]

Abstract

Background Meningiomas are common intradural extramedullary spinal tumors, which arise from arachnoid cap cells in the leptomeninges surrounding the brain or spinal cord. Sensory and motor dysfunction as well as pain were the most common presenting symptoms. Surgical resection remains the primary treatment for spinal intradural extramedullary meningiomas. Traditionally, spinal meningiomas excision requires longer skin incision, bilateral subperiosteal muscle stripping, and total laminectomy. We report a new technique for the treatment of thoracic spinal intradural extramedullary meningioma, which involves the use of unilateral biportal endoscopy (UBE) technique to resect the tumor, and reviewed and analyzed relevant literature.

Case presentation A 69-year-old female patient presented with back pain accompanied by slowly progressive lower limb paresis, and severe pain in the right lower limb. Magnetic resonance imaging suggests a thoracic spinal intradural extramedullary meningioma. She underwent meningioma resection using UBE technique with complete recovery at the follow-up examination 3 months after surgery.

Conclusion This case confirmed the UBE technique can be a good choice for resection of spinal intradural extramedullary meningioma.

Keywords Meningioma, Unilateral biportal endoscopy, Minimally invasive spine surgery, Spinal hypertension syndrome

Background

Meningiomas are the most common primary tumors of the spine [1], which represent 25–46% of all primary intraspinal tumors [2]. They can occur anywhere along the spinal cord with a predilection for the thoracic spine [3]. Typically, Spinal meningiomas are located in the intradural extramedullary space [4]. The majority of patients with spinal meningioma were female (72.83%) [5]. It is well established that surgery is the preferred treatment of choice for spinal meningiomas, as tumor removal usually relieves symptoms with little risk for recurrence [6].

UBE technology belongs to the category of percutaneous spinal endoscopy. Compared to traditional posterior spinal surgery, the entrance of the work and view portals of the UBE technology crosses the intermuscular space to avoid stripping the muscle attached to the spinous process, damaging the posterior branch of the spinal nerve,

*Correspondence:
Wei Zhang
volcano8060@163.com
[1] Spinal Minimally Invasive Center, Hangzhou Hospital of Traditional Chinese Medicine, Huanding Road No. 1630, Hangzhou 310021, China
[2] Department of Orthopaedics, Hangzhou Traditional Chinese Medical Hospital, Affiliated to Zhejiang Chinese Medical University, Tiyuchang Road No. 453, Hangzhou 310007, China

and leading to denervated atrophy of the local muscles. It reduces the incidence of chronic back pain after the surgery. UBE provides a clear surgical field to identify congested epidural venous plexus, degenerative surrounding structures, and neural elements, which are crucial for achieving the best operative results [7]. Compared with single-portal endoscopy, the UBE technology used two portals, including the view portal and the work portal. An independent portal was used for surgical surgery, which effectively broadened the surgical field of vision and made the surgery more flexible. The direction of the portal could be adjusted according to needs [8]. In addition, the UBE technique obtains a safe and complete surgical environment by maintaining stable water dynamics [9]. At the same time, the surgery can be completed with conventional instruments. Therefore, unilateral biportal endoscopy (UBE) technology is now gradually favored by spinal surgeons and even neurosurgeons.

Case presentation

A 69-year-old female presented with a 12-month history of intermittent pelvic/lower extremity numbness. There was chronic back pain, and slowly progressive right lower limb pain and weakness. 1 month of loss of balance and be completely bedridden. In addition, she had to remain in the left decubitus position in bed with right lower limb flexion to relieve the pain in the right lower limb. There was no history of trauma to the spine. On neurological examination, she had hypoesthesia below the navel, hyperreflexia in both lower extremities, as well as a moderate paresis and atrophy in the right leg. Urodynamic study and were normal.

Spinal X-ray did not show abnormal findings. A computed tomography (CT) scan demonstrated that a circular high-density mass measuring about 16 mm × 12.5 mm × 12.5 mm without calcification at the level of intervertebral space 10–11 in the thoracic spinal canal (Fig. 1). A magnetic resonance imaging (MRI) scan revealed an intradural tumor with distinct borders at the $T_{10\text{-}11}$ level that caused serious compression of the thoracic spinal cord (Fig. 2A–B). In a dynamic contrast-enhanced MRI scan, the mass presented as a lateral intradural extramedullary tumor with abundant blood supply (Fig. 2C–D). The size measurement of the mass on MRI is similar to that on CT. In summary, the diagnosis was considered as a thoracic spinal intradural extramedullary meningioma.

The mass was removed under general anesthesia using the UBE technique without fixation. Under general anesthesia, the patient was positioned prone on a radiolucent spine operating table. The operating table was adjusted, so that the thoracic 10–11 ($T_{10/11}$) intervertebral space was perpendicular to the ground. The patient's blood pressure was lowered to 90–110 mm Hg/50–70 mm Hg (MAP ≥ 70 mmHg) with anesthetic drugs to reduce intraoperative bleeding.

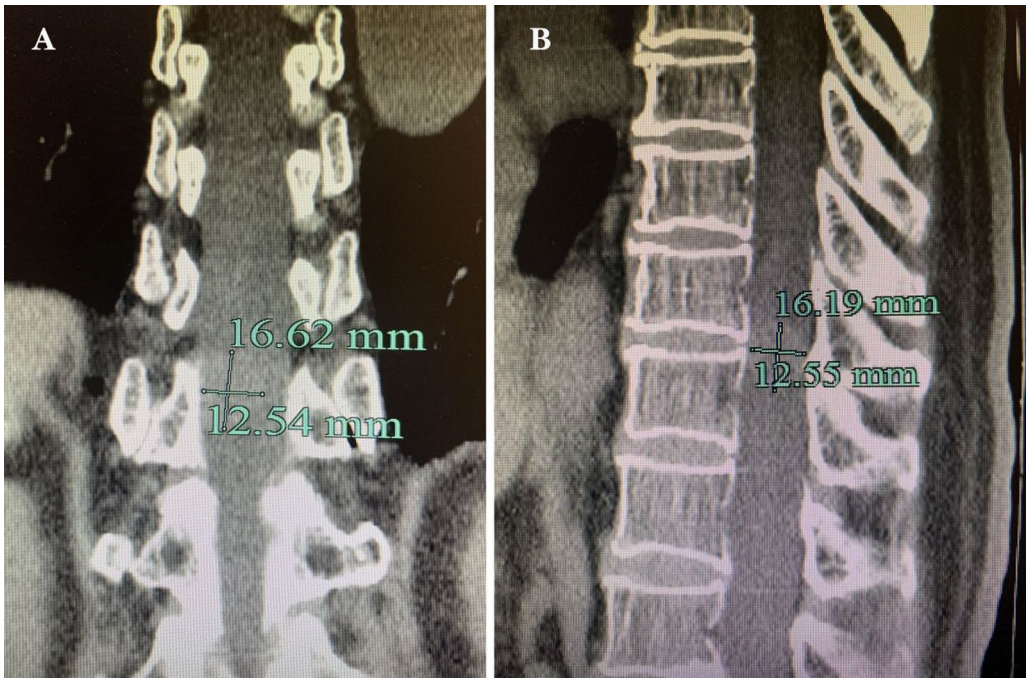

Fig. 1 Pre-surgical CT showed a circular high-density mass. The size of the mass is in the coronal CT scan (**A**) and in sagittal CT scan (**B**)

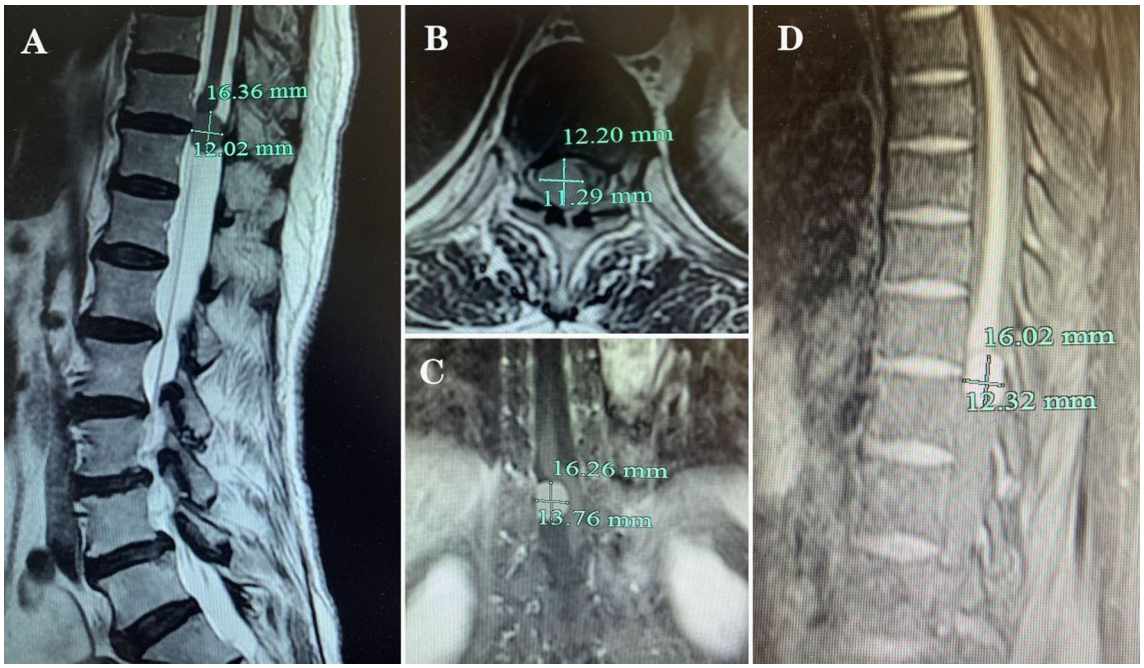

Fig. 2 On conventional MRI (**A**–**B**) and contrast-enhanced MRI (**C**–**D**), the spinal cord is severely compressed and pushed sideways by an spinal canal tumor with distinct borders at the $T_{10\text{-}11}$ level

The T10/11 intervertebral space, approximately the center of the tumor, was confirmed and focused. The initial target point of the endoscope and the instrument was located at the junction of the spinous process and lamina on the right side of the T10 vertebral body at the level of T10/11 intervertebral space, and a horizontal line was made around the target point. A marked line was drawn along the inner edge of the pedicle of the T10 and T11 vertebrae. Two points, 1.5 cm away from the far and near sides of the junction point of the aforementioned two lines, were used as the body surface positioning points of the view portal and work portal, respectively (Fig. 3A–C).

Under the guidance of C-arm fluoroscopy, two transverse skin incisions were made to form the view (caudal side) and work (cranial side) portals. The length of the skin incision was about 1.0–1.5 cm. The surgeon stood on the right side. A guide rod was inserted into each of the two incisions after the incision of the skin, subcutaneous tissue, and fascia layer. Fluoroscopy determined that the two positioning rods crossed at the ideal target point. Serial dilators were used to separate the back muscle and create the view and work portals. A 30 degree endoscope connected to the irrigation system was inserted through the view portal, and then, the irrigation system was turned on for continuous irrigation. A natural gravity irrigation system (about 70–100 cm above the table) was used for continuous saline irrigation. The plasma radiofrequency wand was used through the work portal to clean the residual soft tissue on the lamina surface near the target point and control bleeding so as to ensure the clarity of the surgical field.

The first target point was exposed using a plasma radiofrequency wand. Then, the surgical field was expanded to the periphery by adjusting the direction of the endoscope and fully expose the lamina at the upper and lower edges of the T10–11 space. Intraoperative fluoroscopy determines the upper and lower boundaries of the tumor according to preoperative imaging data (Fig. 3D–E). Partial hemi-laminectomy within the above range was started with an automatic drill, and then, remaining drilled lamina and ligamentum flavum were removed with laminectomy rongeurs to expose the dural sac. A sharp scalpel was used to make a longitudinal incision of the tense dura, which was propped up by the tumor, with an incision about 2 cm in length. Then, it was found that the spinal cord was squeezed toward the opposite side by the tumor, and there was no adhesion between the two. On the contrary, the tumor was partially adhered to the dura mater. The adhesions were dissected with a nerve dissector, and then, the tumor was removed in fractions with a forceps, and applying a smaller models of plasma radiofrequency wand for hemostasis. The dural origin is coagulated to reduce the recurrence rate. The incised dura was sutured with a 7–0-diameter thread (Fig. 4A–E). A drainage catheter was inserted to prevent postsurgical

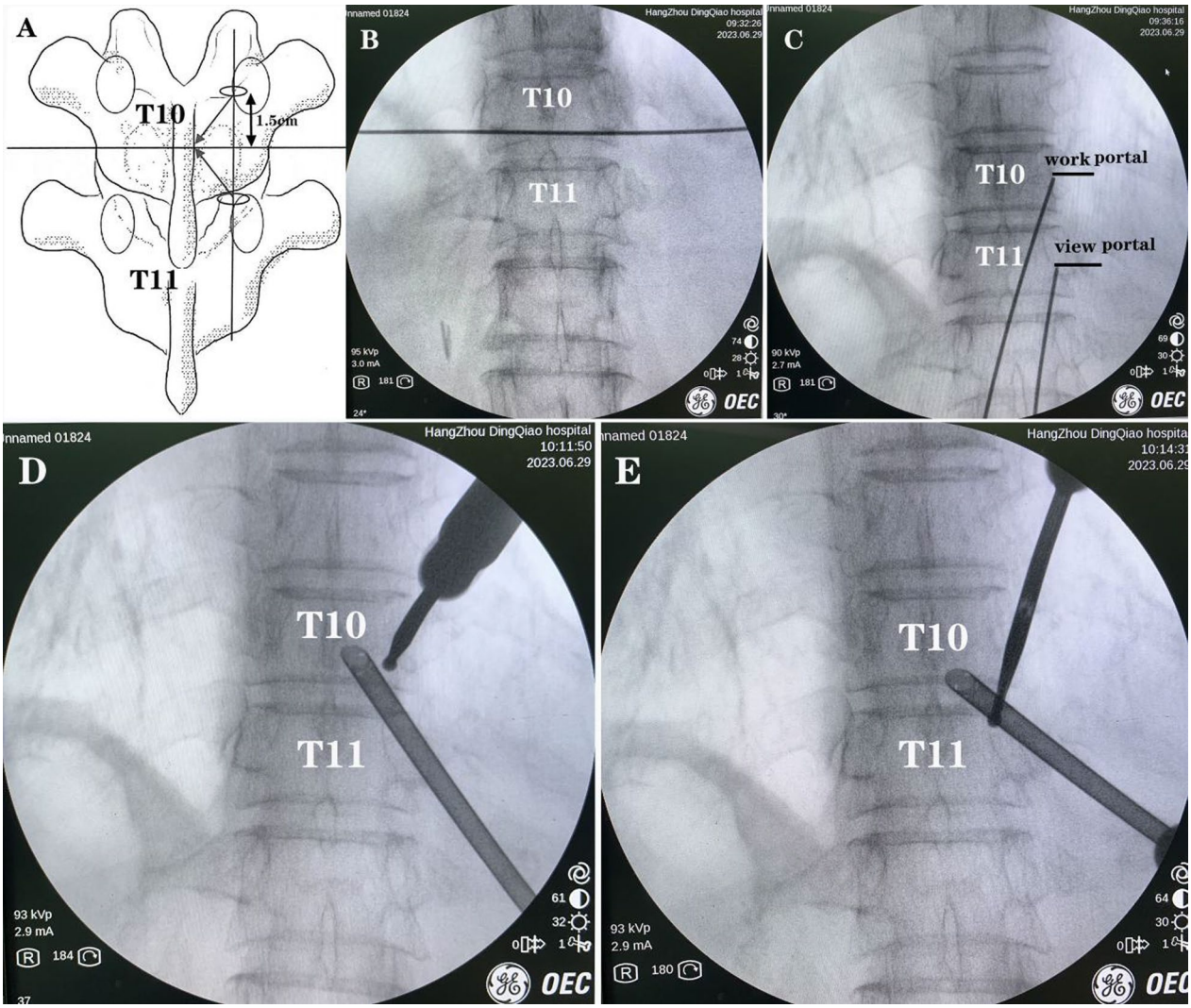

Fig. 3 Based on the results of preoperative imaging examination, intraoperative fluoroscopy is used to determine the tumor location, view portal, work portal (**A**–**C**), and the upper and lower boundaries of the tumor (**D**, **E**)

epidural hematoma. The skin was sutured layer by layer after extruding the remaining saline for irrigation.

After anesthesia resuscitation, there is an increase in blood pressure, heart rate and respiration, and muscle hypertonia in the extremities. The patient complained of back pain, neck pain and headache, chest tightness, and a feeling of near-death. The patient had to be re-intubated five minutes after extubation. After 6 h of surgery, the patient's blood pressure, heart rate, and respiration tend to stabilize, and the tracheal tube was removed after the sedatives stopped gradually. The patient described the disappearance of chest tightness and near-death feelings, but neck pain and headache remained. Physical examination revealed that muscle tone in the extremities was relaxed but still higher than normal. And muscle tension returned to normal 12 h after surgery, with relief of neck pain and headache. There was no postoperative cerebrospinal fluid leakage. Three days postoperatively, the drainage tube was removed, and the total drainage fluid was 100 ml. The patient was able to start walking with the protection of a thoracic spine brace 5 days after surgery without pain in the lower extremities. Histopathological examination revealed a meningioma, and positive for the immunohistochemical staining with epithelial membrane antigen (EMA) and S-100 (Fig. 4F).

Discussion

The current case report demonstrates that UBE technology can effectively remove thoracic spinal intradural extramedullary meningioma and achieve good results.

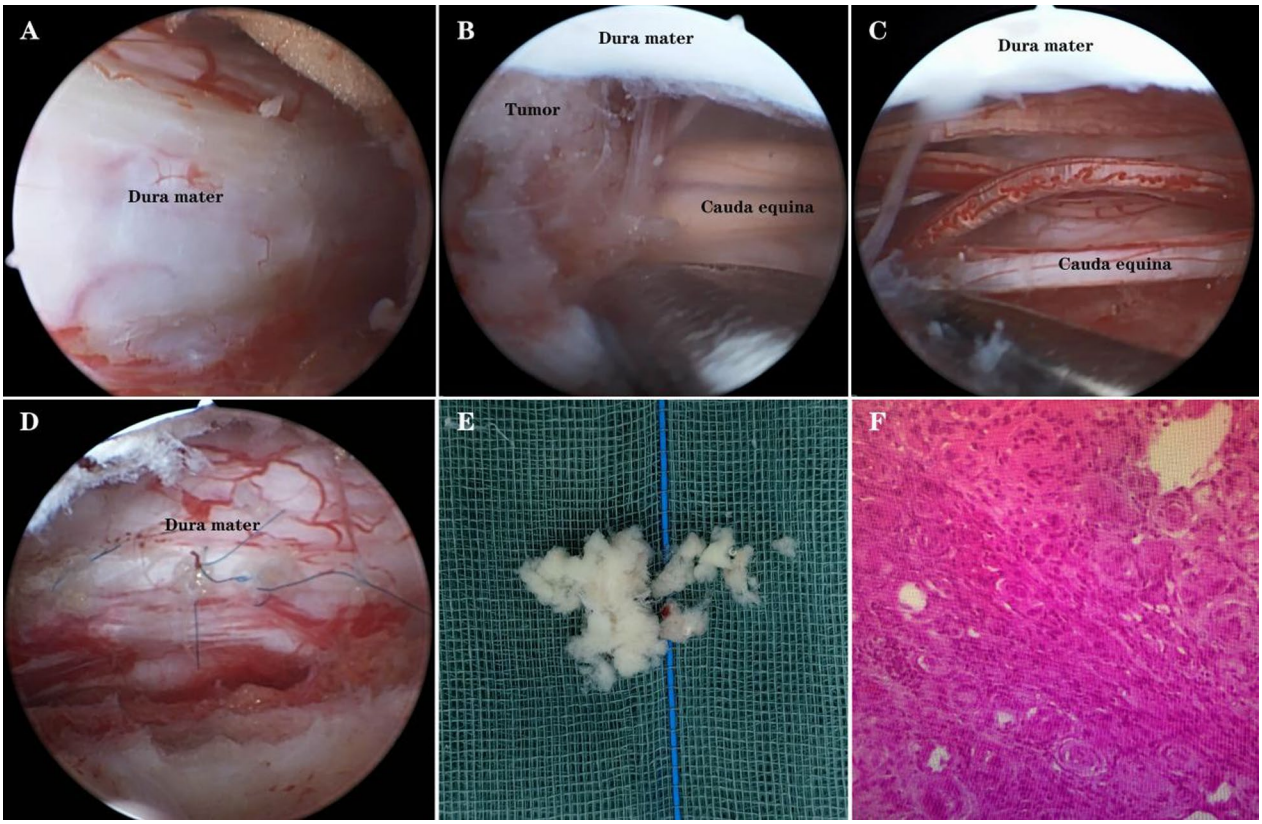

Fig. 4 Intraoperatively, the dural incision, tumor resection, and dural suture were performed (**A**–**E**), and the postoperative pathology confirmed meningioma (**F**)

The surgery time under UBE surgery was about 90 min, including 60 min after dural incision. And postoperative cerebrospinal fluid leakage was not detected. The postsurgical imaging data were obtained 5 days after the surgery. The intradural extramedullary tumor was completely removed under UBE surgery to restore the spinal canal volume, accompanied by an unobstructed cerebrospinal fluid flow in MRI scans postoperatively (Fig. 5). According to the postoperative CT scans, the thoracic spine was not unstable, because the extent of the thoracic lamina to be removed is small and can be allowed by spinal stabilization (Fig. 6).

The diagnosis of meningioma is based on the patient's symptoms, signs, imaging examination, and postoperative pathological diagnosis. In addition to the signs and symptoms, the early diagnosis of meningioma mainly depends on imaging examination [10]. X-rays usually show no abnormal findings, while CT scans can reveal masses in the spinal canal that are close to the density of the spinal cord tissue, and partially calcified tumors can be displayed as high-density masses or scattered spots in the spinal canal. MRI scanning can clearly detect a mass in the spinal canal, with the spinal cord or cauda equina being pushed to one side by the mass. Spinal meningioma showed equal or slightly lower than the spinal cord on T1-weighted images and T2-weighted images, and after enhancement, it appears as uniform enhancement [11]. The patient mentioned in the article presented with severe pain in the right lower limb. MRI scanning revealed space-occupying lesions in the spinal canal with similar signals to the spinal cord. X-ray did not reveal any abnormalities, and CT scan did not reveal calcification of the mass.

Meningioma is a benign tumor, but it can cause severe spinal cord or nerve compression and even paralysis as it grows. Therefore, once the diagnosis is clear, it should be resected early to obtain a good prognosis as long as there are no surgical contraindications [12]. The commonly used surgical methods are as follows. The first surgical method is posterior total laminectomy and tumor extraction. It is a classic approach with the advantages of short surgical time and complete exposure, and the disadvantages of postoperative spinal instability requiring pedicle screw fixation when wide laminectomy disrupting the facet joint or multilevel laminectomy has been performed [13]. The second method is posterior semi-laminectomy

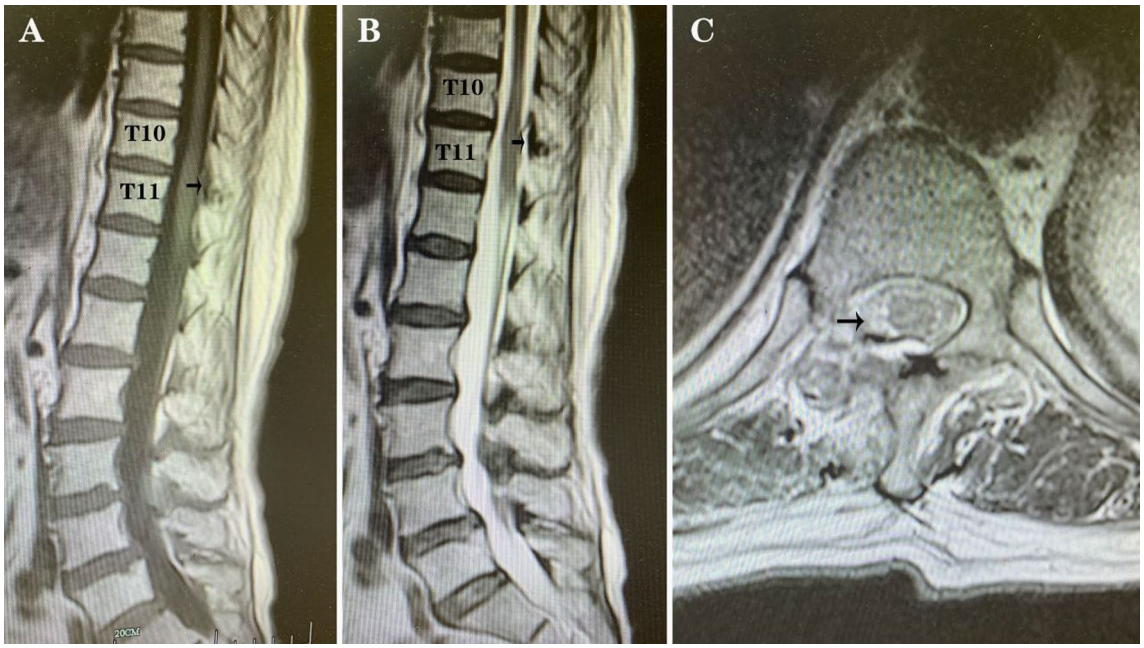

Fig. 5 Postoperative MRI (T1-weighted: **A**, T1-weighted: **B**, and the axial MRI: **C**) showed that the tumor was removed completely (arrows) and the cerebrospinal fluid flow was restored

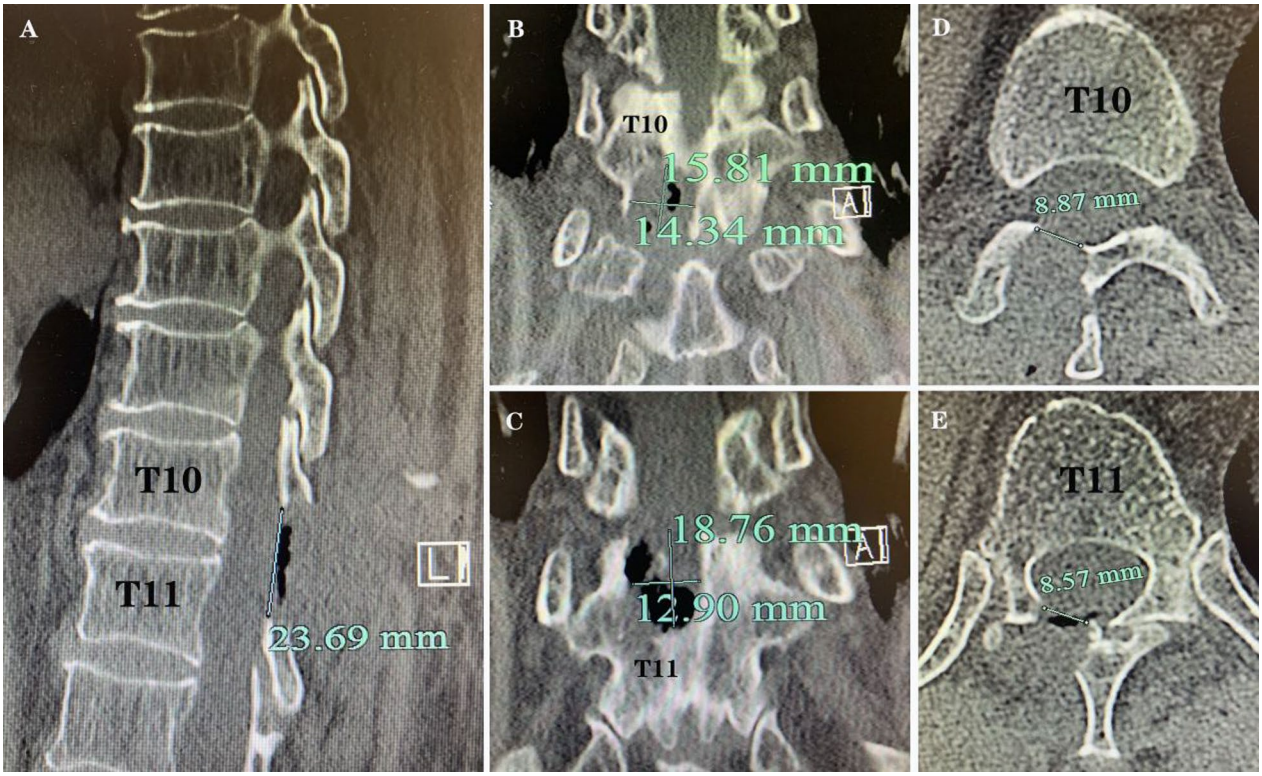

Fig. 6 Postoperative CT (sagittal CT scan: **A**, the coronal CT scans: **B** and **C**, and axial CT scans: **D** and **E**) indicated that the removal of bone tissue was less extensive and had less impact on spinal stability, because the facet joint was intact, and no additional internal fixation was installed

and tumor extraction. There is less-invasive surgery than a total laminectomy, with less interference on nerves and spinal cord, and a single thoracic laminectomy can be performed without internal fixation [14]. The third surgical method is laminoplasty after spinal meningioma resection [3]. The aforementioned open surgery had the advantages of clear vision and reliable efficacy. However, surgical procedures usually lead to frequent complications, such as larger iatrogenic trauma, higher bleeding volumes, and a longer hospitalization time because of the need for extensive dissection of the surrounding muscles, fascia, and ligaments. Additionally, they often affect the daily life and work of the patient because of complications, such as persistent back pain, spinal stiffness, and weakness [15]. The UBE technique for an extradural mass had limited reports. Wang and colleagues describe five cases that clarify how to use UBE to completely remove extradural mass lesions with obvious improvement of symptoms. Results showed that four patients were confirmed as having an epidural cyst and one patient was diagnosed with hemangioma [16]. In this study, the UBE technique was used to resect a thoracic spinal intradural extramedullary meningioma. It has the advantages of less trauma, less bleeding, and faster recovery, with less damage to the posterior soft tissue and bone structure and no need for additional internal fixation.

Common complications of UBE technique for resection of thoracic spinal meningioma include cerebrospinal fluid leakage and spinal hypertension syndrome. The management of complications is described as follows.

(1) Leakage of cerebrospinal fluid.

The cerebrospinal fluid leakage is one of the common complications of spinal canal surgery. Most patients were found to have dural tear during the operation, and postoperative drainage was also observed. Wang and colleagues reported that the incidence of intraoperative or postoperative cerebrospinal fluid leakage is 2.49% due to tearing of the dura mater during UBE surgery for lumbar spinal stenosis [17]. Its management can be summarized as wound drainage was removed followed by wound sutures, prophylactic antibiotics, dexamethasone, elevated head position, and continuous lumbar subarachnoid drainage treatment [18]. In this case, no cerebrospinal fluid leakage was observed during postoperative drainage.

(2) Spinal hypertension syndrome.

Spinal hypertension is a unique complication of endoscopic spinal surgery requiring water irrigation. It is often caused by intraoperative dural tear and high irrigation pressure. Yuan and colleagues treated 50 cases of calcified lumbar disc herniation with percutaneous endoscopic lumbar discectomy technique, of which 1 case diagnosed as spinal hypertension syndrome during the surgery [19]. UBE technology requires general anesthesia for patients. When the patient's heart rate and blood pressure are found to rise sharply during the operation, or there is a rupture of the dural, the occurrence of spinal hypertension should be vigilant. In these cases, the height and flow rate of irrigation fluid should be reduced, appropriate dehydration drugs and hormones should be applied, and the operation should be completed as soon as possible. Patient with spinal hypertension may experience neck pain during the surgery [19]. As well as neck pain, one or more of neurological dysfunction syndromes, such as headache, clumsiness, irritability, visual disturbance, dizziness, tinnitus, seizure, the near-death sensations, and dystonia, were found in our research. Treatment for the syndrome includes continued tracheal intubation, sedative medications, appropriate application of antihypertensive medications to control blood pressure, and necessary dehydrating medications and hormones. And symptoms and signs are generally completely relieved within 24 h after surgery. In this case, the patient underwent a 60 min operation without significantly reducing the irrigation water pressure after the dural incision to ensure a clear surgical field of vision. Although dehydration drugs and hormones (80 mg of methylprednisolone) were used during the operation, spinal hypertension syndrome still observed. After the above treatment, the patient's symptoms and signs were completely relieved 12 h after surgery.

Conclusion

We successfully removed spinal intradural extramedullary meningioma using a biportal endoscopic posterior approach. The biportal endoscopic approach may have advantages, such as minimizing trauma to the normal structures, magnified endoscopic view, and early recovery after the surgery. This case confirmed the UBE technique may be used as an alternative surgical treatment for spinal intradural extramedullary meningioma.

Abbreviations

UBE	Unilateral biportal endoscopy
CT	Computed tomography
MRI	Magnetic resonance imaging
T10/11	Intervertebral space of thoracic 10 and thoracic 11
MAP	Mean arterial pressure
EMA	Epithelial membrane antigen

Acknowledgements

The authors would like to thank the patient and his family for cooperating in this study.

Author contributions
RS: drafting and revising the manuscript, and collecting and supervising the case medical history and investigations, WC: designing figures and arranging them. WZ and HP: collecting case medical history and investigations, and revising final manuscript. All authors read and approved the final manuscript.

Funding
This work was supported by the Natural Science Foundation of Zhejiang Province (LY19H060008).

Availability of data and materials
Not applicable.

Declarations

Ethics approval and consent to participate
This study protocol was approved by the Research Ethics Board of Hangzhou Traditional Chinese Medical Hospital Affiliated to Zhejiang Chinese Medical University. The patient signed a written informed consent form for enrolment in this study.

Consent for publication
Written informed consent was obtained from participant for publication of this case report and accompanying images.

Competing interests
The authors declare that there are no competing interests.

Received: 5 September 2023 Accepted: 23 December 2023
Published online: 15 January 2024

References

1. Bisht S, Laurente R, Joshi KG. Circumferential intradural meningioma of the thoracic spine: case report and literature review. Surg Neurol Int. 2021;12:120.
2. Albanese V, Platania N. Spinal intradural extramedullary tumors. Personal experience. J Neurosurg Sci. 2002;46(1):18–24.
3. Ravindra VM, Schmidt MH. Management of spinal meningiomas. Neurosurg Clin N Am. 2016;27(2):195–205.
4. Hohenberger C, Hau P, Schebesch KM, Kölbl O, Riemenschneider MJ, Pohl F, et al. Spinal meningiomas. Neurooncol Adv. 2023;5(Suppl 1):i112–21.
5. El-Hajj VG, Pettersson-Segerlind J, Fletcher-Sandersjöö A, Edström E, Elmi-Terander A. Current knowledge on spinal meningiomas epidemiology, tumor characteristics and non-surgical treatment options: a systematic review and pooled analysis (part 1). Cancers (Basel). 2022;14(24):6251.
6. El-Hajj VG, Pettersson-Segerlind J, Fletcher-Sandersjöö A, Edström E, Elmi-Terander A. Current knowledge on spinal meningiomas-surgical treatment, complications, and outcomes: a systematic review and meta-analysis (part 2). Cancers (Basel). 2022;14(24):6221.
7. Aygun H, Abdulshafi K. Unilateral biportal endoscopy versus tubular microendoscopy in management of single level degenerative lumbar canal stenosis: a prospective study. Clin Spine Surg. 2021;34(6):E323–8.
8. Ma X, Li W, Gao S, Cao C, Li C, He L, et al. Comparison of unilateral biportal endoscopic discectomy versus percutaneous endoscopic lumbar discectomy for the treatment of lumbar disc herniation: a systematic review and meta-analysis. Medicine (Baltimore). 2022;101(39):e30412.
9. Hong YH, Kim SK, Hwang J, Eum JH, Heo DH, Suh DW, et al. Water dynamics in unilateral biportal endoscopic spine surgery and its related factors: an in vivo proportional regression and proficiency-matched study. World Neurosurg. 2021;149:E836–43.
10. Tariq A, Sohail A, Shah Z, Bakhshi S, Shamim MS. Spinal meningiomas: management and outcomes. J Pak Med Assoc. 2023;73(7):1548–50.
11. Takashima H, Takebayashi T, Yoshimoto M, Onodera M, Terashima Y, Iesato N, et al. Differentiating spinal intradural-extramedullary schwannoma from meningioma using MRI T2 weighted images. Br J Radiol. 2018;91(1092):20180262.
12. Ravindra VM, Schmidt MH. Spinal meningiomas: diagnosis, surgical management, and adjuvant therapies. Neurosurg Clin N Am. 2023;34(3):425–35.
13. Xu F, Tian Z, Qu Z, Yao L, Zou C, Han W, et al. Completely ossified thoracic intradural meningioma in an elderly patient: a case report and literature review. Medicine (Baltimore). 2020;99(25):e20814.
14. Tredway TL, Santiago P, Hrubes MR, Song JK, Christie SD, Fessler RG. Minimally invasive resection of intradural-extramedullary spinal neoplasms. Neurosurgery. 2006;58:ONS52.
15. Thavara BD, Kidangan GS, Rajagopalawarrier B. Analysis of the surgical technique and outcome of the thoracic and lumbar intradural spinal tumor excision using minimally invasive tubular retractor system. Asian J Neurosurg. 2019;14(2):453–60.
16. Wang T, Yu H, Zhao SB, Zhu B, Chen L, Jing JH, et al. Complete removal of intraspinal extradural mass with unilateral biportal endoscopy. Front Surg. 2022;9:1033856.
17. Wang B, He P, Liu X, Wu Z, Xu B. Complications of unilateral biportal endoscopic spinal surgery for lumbar spinal stenosis: a systematic review of the literature and meta-analysis of single-arm studies. Orthop Surg. 2023;15(1):3–15.
18. Tian Y, Yu KY, Wang YP, Qian J, Qiu GX. Management of cerebrospinal fluid leakage following cervical spine surgery. Chin Med Sci J. 2008;23(2):121–5.
19. Yuan AL, Shen X, Chen B. Treatment of calcified lumbar disc herniation by intervertebral foramen remolding: a retrospective study. J Pain Res. 2022;15:1719–28.

Publisher's Note